

TCL1 Expression and Epstein-Barr Virus Status in Pediatric Burkitt Lymphoma

Michael A. Teitell, MD, PhD,^{1,2} Mark A. Lones, MD,^{3,4} Sherrie L. Perkins, MD, PhD,^{4,5} Warren G. Sanger, PhD,^{4,6} Mitchell S. Cairo, MD,^{4,7} and Jonathan W. Said, MD¹

Key Words: T-cell leukemia-1; TCL1; Oncogene; Epstein-Barr virus; Burkitt lymphoma; Pediatric; Children; Adolescent; Chromosome abnormalities; Karyotype

DOI: 10.1309/77V7U4E03V69QHRR

Abstract

Elevated T-cell leukemia-1 (TCL1) oncoprotein expression might promote human Burkitt lymphoma (BL) because increased TCL1 causes Burkitt-like lymphomas in TCL1 transgenic mice. Epstein-Barr virus (EBV) infection has been implicated as a cause of increased TCL1 expression in multiple BL cell lines, suggesting a critical connection between EBV and TCL1-induced BL. The TCL1 expression and EBV status of 14 sporadic pediatric BL cases was determined by immunohistochemical staining for TCL1 and in situ hybridization for EBV-encoded RNA (EBER). Our results showed TCL1 protein in 11 cases, predominantly in the nucleus with strong-intensity staining. EBER was positive in 4 cases, with 3 of these cases also TCL1+. In the 10 cases that were EBER-, TCL1 was strongly positive in 8. These data indicate that the TCL1 oncoprotein is expressed strongly in most pediatric BL cases. However, persistent EBV is not essential for increased TCL1 expression, although elevated TCL1 and c-MYC coexpression might cooperate in the development of most pediatric and adult BL cases.

Aberrant T-cell leukemia-1 (*TCL1*) proto-oncogene expression is implicated in childhood and adult peripheral T-cell leukemia/lymphoma and might have a role in adult B cell malignant neoplasms of germinal center (GC) origin. In T-cell cancers, dysregulation is due to recurrent chromosomal rearrangements in the thymus involving the *TCL1* locus at 14q32.1 and T cell receptor (*TCR*) gene regulatory elements at 14q11.2 (*TCR α δ* locus) or 7q35 (*TCR β* locus).^{1,2} *TCL1* protein binds the serine/threonine kinase Akt and stimulates its hyperactivation and transport from the cytoplasm to the nucleus. This follows activation of Akt-stimulating signaling pathways, such as antigen receptor engagement in lymphocytes.³⁻⁷ Inappropriately augmented activation of Akt has been proposed as a mechanism by which dysregulated *TCL1* expression promotes malignant transformation through increased survival and cell proliferation.^{3,7,8} Enforced *TCL1* expression in transgenic mice also results in mature B- and T-cell tumors, providing support for the oncogenic potential of dysregulated *TCL1* expression in human lymphoid cancers.^{7,9}

During B-cell development, *TCL1* protein expression remains high from early precursors in the bone marrow through preselected mantle cell stages of peripheral maturation.^{10,11} Subsequently, *TCL1* expression is reduced in antigen-stimulated GC B cells, followed by gene silencing and loss of protein expression in memory B and plasma cells. This physiologic down-regulation of *TCL1* in GC follicles parallels that of the antiapoptotic oncoprotein *bcl-2* and might facilitate removal of B cells with inappropriate immunoglobulin-antigen affinities by apoptosis.⁸ However, a large number of GC- and post-GC-derived B-cell tumors, including diffuse large B cell lymphoma (DLBCL) and Burkitt lymphoma (BL), exhibit higher levels of *TCL1* oncoprotein expression than that seen

in follicle center B cells.^{8,10,11} In contrast with chronic T-cell malignant neoplasms, gene rearrangements do not seem to dysregulate *TCL1* expression in mature B-cell tumors.^{12,13}

Several studies have suggested a role for epigenetic modifications, such as DNA methylation, in controlling *TCL1* expression during terminal B-cell differentiation.^{12,13} With this in mind, a possible mechanism for up-regulated or continued high-level *TCL1* expression in mature B-cell tumors is defective epigenetic regulation that fails to silence *TCL1* during GC B-cell maturation. An additional possibility is that Epstein-Barr virus (EBV) infection, seen in more than 90% of endemic African BL cases and 15% to 20% of sporadic BL cases, positively regulates *TCL1* expression and overrides *TCL1* silencing in terminal B-cell development.¹⁴ In this regard, the objectives of the present study were to evaluate *TCL1* expression and EBV status in primary pediatric BL, evaluate a possible role for *TCL1* in the pathogenesis of BL in the pediatric age group, and help determine a role for EBV in regulating *TCL1* expression levels.

Materials and Methods

Patient Selection

Cases of BL were chosen from those meeting eligibility criteria for Children's Cancer Group (CCG) treatment protocol CCG-5961 (French-American-British LMB 96 Treatment of Mature B-Cell Lymphoma/Leukemia: an SFOP LMB 96/CCG-5961/UKCCSG NHL 9600 cooperative study).¹⁵⁻¹⁸ Before patients were enrolled, the participating CCG institutions obtained appropriate institutional review board approval of the protocol and informed consent for treatment for all patients.

Pretreatment Evaluation

All patients underwent complete history and physical examination with laboratory studies, including CBC count and lactate dehydrogenase measurement. Pathologic staging included bilateral bone marrow aspirates (biopsies optional), cerebrospinal fluid examination, and appropriate radiologic studies. Central nervous system involvement was defined as the presence of any L3 blasts or lymphoma cells in the cerebrospinal fluid, cranial nerve palsy, clinical signs of spinal cord compression, isolated intracerebral mass, or parameningeal extension. Bone marrow was classified as involved if any L3 blasts or lymphoma cells were present. Radiologic investigations included at least a chest radiograph (posterior-anterior and lateral), abdominal ultrasound, and abdominal computed axial tomography scan or magnetic resonance imaging for stage of localized disease. Gallium scan was optional. The clinical stage of disease was determined using a modified Murphy classification.¹⁹

Pathologic Evaluation

For the cases in this study, biopsy tissue samples were preserved in formalin fixative and routinely processed and evaluated at the primary institution. Paraffin blocks or unstained sections from the biopsies were submitted to the CCG Pathology Center, Children's Hospital, Columbus, OH, for central pathology review, including morphologic evaluation and immunophenotyping studies. Biopsy specimens from 14 pediatric patients with BL, sporadic type, at primary diagnosis were evaluated. The protocol cases were classified as BL according to the characteristic morphologic, immunophenotypic, and cytogenetic features as described in the revised European-American Lymphoma Classification²⁰ or the World Health Organization Classification.²¹ The standard immunophenotyping panel for these cases included antibodies to CD20, CD79a, CD3, CD45RO, and terminal deoxynucleotidyl transferase as described previously.²²

TCL1 Immunohistochemical Analysis and Scoring

Detection of *TCL1* was performed on paraffin sections with a rabbit polyclonal antiserum to *TCL1* using an immunoperoxidase method as previously described.^{8,11} A positive result was interpreted as brown staining localized within the cytoplasm or nucleus of neoplastic cells. Scoring was recorded for the percentage of neoplastic cells staining positively along with the intensity of staining (scored visually 1+ [weak], 2+ [moderate], or 3+ [strong]). Negative control samples were prepared by substituting the primary rabbit antiserum to *TCL1* with preimmune rabbit serum. Positive control tissue samples were paraffin sections of hyperplastic tonsil.

In Situ EBV-Encoded RNA Hybridization

Detection of EBV was performed with in situ hybridization on paraffin sections using a fluorescein isothiocyanate-conjugated oligonucleotide probe to EBV-encoded RNA (EBER; BioGenex Laboratories, San Ramon, CA) with an immunoperoxidase method as previously described.²³ A positive result was interpreted as brown staining localized within the nucleus of neoplastic cells. Positive control tissue samples were paraffin sections of EBV+ Hodgkin lymphoma. In addition, a fluorescein-labeled oligo (dT) probe (BioGenex Laboratories) was used as a positive control for detecting messenger RNA.

Cytogenetic Evaluation

Cytogenetic analysis was performed on biopsy specimens at the primary institution with G-banded karyotypes. The karyotypes were submitted for central cytogenetics review as follows: (1) 2 original karyotypes of each abnormal clone, and (2) 2 karyotypes of normal metaphase cells for each normal case. The central cytogenetics review was performed by a member of the CCG Cytogenetics Committee (W.G.S.). The karyotype results were reported using the 1995 International

System for Human Cytogenetic Nomenclature.²⁴ Karyotypes were classified according to the most abnormal clone.

Fluorescence In Situ Hybridization

Fluorescence in situ hybridization (FISH) procedures were performed on 4 to 5 μ m unstained paraffin tissue sections using the LSI *MYC* Dual-Color Break-apart Probe (Vysis, Downers Grove, IL) and the LSI *IGH/MYC/CEP8* Dual-Fusion Translocation Probe (Vysis). Before hybridization, the slides were pretreated using the VP2000 (Vysis) automated slide processor using the program specified for paraffin slides.

Briefly, the program included deparaffinization of the slides followed by dehydration, 0.2N hydrochloric acid treatment for 15 minutes, and incubation in sodium thiocyanate for 20 minutes at 80°C. The slides then were digested in protease for 15 minutes at 37°C, rinsed, and dehydrated. For FISH, 10 μ L of the probe mixture was placed on the pretreated tissue section and coverslipped. The probe and target DNA were codenatured at 75°C for 5 minutes followed by an overnight hybridization using a HybRite (Vysis) automated FISH hybridization chamber. After hybridization, the slides were washed for 2 minutes in 2 \times standard saline citrate (SSC)/0.1% NP-40 (Vysis) at 72°C followed by 2 minutes in 2 \times SSC/0.1% NP-40 at room temperature. The slides were counterstained with 4',6-diamidino-2-phenylindole at a concentration of 125 ng/mL in antifade solution. Analysis was performed on an Olympus BX61 fluorescence microscope (Scientific Instrument, Culver City, CA) equipped with appropriate filters and Cytovision FISH system image capture software (Applied Imaging, Santa Clara, CA).

For the *myc* break-apart probe, 150 to 200 cells were scored for a "separation" of the green and red signal that was indicative of a rearrangement of the *myc* gene region at 8q24.1. The false-positive rate for this FISH test on paraffin tissue sections, as established before this study, is 0% to 15%.

For *IGH/MYC/CEP8* probes, 150 to 200 cells were scored for the presence of the t(8;14)(q24.1;q32) as evidenced by juxtaposition of the red (*myc*) and green (*IgH*) signals forming a yellow "fusion" signal. The false-positive rate for this FISH system on paraffin tissue sections, as established before this study, is 0% to 10%.

Results

We evaluated 14 biopsy specimens diagnosed as BL from 14 pediatric patients. The clinical features of the 14 patients are summarized in **Table 1**. Children and adolescents in this study ranged in age from 2 to 16 years (median,

Table 1
Clinical Features of Pediatric Burkitt Lymphoma in 14 Patients

Case No./Sex/Age (y)	Murphy Stage	Primary Site
1/M/3	I	Tonsil
2/M/7	I	Neck
3/M/8	II	Nasopharynx
4/M/14	II	Nasopharynx
5/M/2	III	Intestine
6/M/2	III	Intestine
7/M/6	III	Abdomen
8/F/7	III	Intestine
9/M/10	III	Intestine
10/M/11	III	Abdomen
11/M/12	III	Intestine
12/M/13	III	Intestine
13/F/13	III	Abdomen
14/M/16	IV, + central nervous system	Orbit

10 years). The male/female ratio was 6:1. The clinical stage of disease was determined according to the Murphy classification as follows: I, 2 cases; II, 2 cases; III, 9 cases; and IV, 1 case. The primary site of involvement included the following: intestine, 6 cases; abdomen, 3 cases; nasopharynx, 2 cases; and neck, orbit, and tonsil, 1 case each. These findings are similar to the reported male predominance and frequent sites of manifestation for sporadic BL in the pediatric age group.^{21,25,26}

In all 14 cases, the tumor biopsy tissue samples contained typical morphologic features of BL **Image 1**, including monomorphic, medium-sized cells containing round nuclei with multiple nucleoli (2 to 5) and a moderate amount of cytoplasm. A starry-sky pattern was present owing to scattered apoptosis and associated macrophages. Immunohistochemical

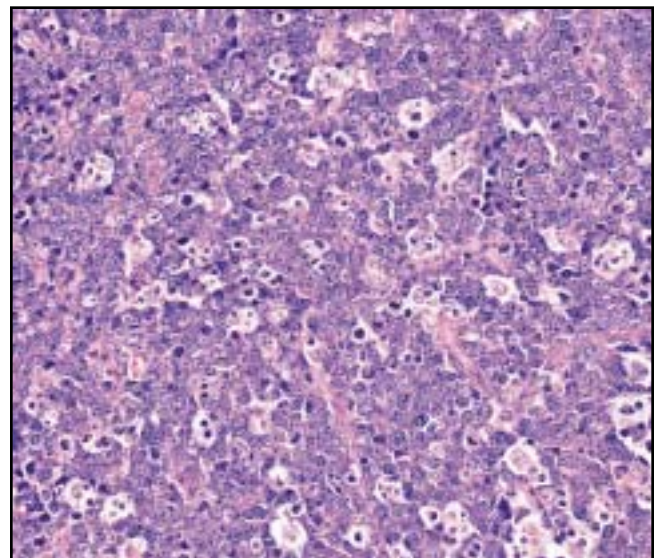


Image 1 Pediatric Burkitt lymphoma (H&E, original magnification \times 150).

staining demonstrated a B-cell phenotype, with all 14 cases positive for CD20 and CD79a, negative for T-cell markers CD3 and CD45RO, and negative for the precursor marker terminal deoxynucleotidyl transferase (data not shown).²⁷ None of the cases had bone marrow involvement characteristic of precursor B-cell acute lymphoblastic leukemia.

Cytogenetic karyotype studies (Table 2) in 10 cases were abnormal, with 9 cases (1, 4, 6, 7, and 9-13) showing the typical t(8;14)(q24.1;q32) causing a *c-MYC/IgH* translocation, and 1 case (14) showing a variant *c-MYC* translocation t(8;22)(q24.1;q11), characteristic of BL.^{28,29} The other 4 cases without cytogenetic abnormalities on karyotype studies were evaluated by FISH studies and demonstrated *c-MYC* translocations in all 4 cases, including 3 cases with *c-MYC/IgH* translocations.

TCL1 oncoprotein expression was positive in 11 BL cases (79%) in immunohistochemical analysis (Image 2). TCL1 staining of neoplastic cells was localized predominantly in the nucleus with strong intensity, along with weak staining in the cytoplasm in all positive cases (Table 3). TCL1 was detected in the majority of neoplastic cells (range, 60%-100%) in 10 of 11 cases. The TCL1 staining intensity in BL was considerably stronger, particularly in the nucleus, than the staining intensity of TCL1 in reactive follicle center cells of hyperplastic lymphoid tissue, consistent with increased TCL1 oncoprotein expression in BL (Image 3).

In situ hybridization for EBER was positive in 4 BL cases (29%; Table 3) (Image 4). EBER staining was restricted to the nucleus in all 4 cases. Among these EBER+ cases, 3 cases also were TCL1+. In the 10 EBER- cases, 8 were TCL1+ (Table 3).

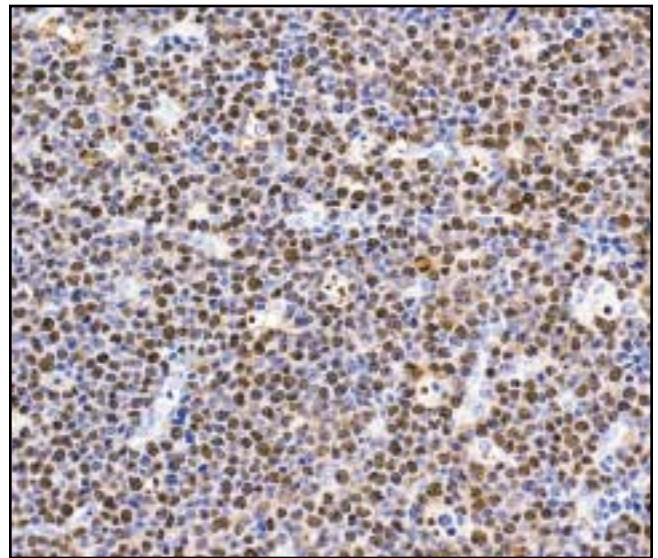


Image 2 T-cell leukemia-1 (TCL1) expression in pediatric Burkitt lymphoma. Immunohistochemical stain for TCL1 oncoprotein exhibits strong immunoreactivity (brown stain) in the nucleus of Burkitt lymphoma cells (diaminobenzidine chromogen, hematoxylin counterstain, original magnification $\times 150$).

Discussion

Aberrant TCL1 expression promotes mature lymphoid malignant neoplasms in humans and transgenic mice. An association between elevated TCL1 expression and BL has been shown in cell lines and in a small number of primary BL samples, presumably from adult patients.^{2,10-12,30} In the present

Table 2
Cytogenetics in 14 Patients With Pediatric Burkitt Lymphoma

Case No.	Karyotype	FISH	
		t(<i>c-MYC</i>)	t(<i>c-MYC/IgH</i>)
1	46,XY,t(8;14)(q24.1;q32)[cp17]/46,XY[cp3]	NA	NA
2	46,XY	+	+
3	46,XY	+	-
4	46,XY,t(8;14)(q24.1;q32)[cp2]/47,XY,t(8;14)(q24.1;q32),+19[cp5]	NA	NA
5	No growth	+	+
6	48,XY,+X,+3,t(9;14)(p13;q32)[cp3]/47,XY,+X,t(8;14)(q24.1;q32)[cp2]/46,XY,t(8;14)(q24.1;q32),t(9;14)(p13;q32)[cp2]/46,XY[cp19]	NA	NA
7	49,XY,t(8;14)(q24.1;q32),+12,add(13)(q32),+add(18)(q22),+20[cp16]/49,XY,t(1;17)(q32;p11.2),t(8;14)(q24.1;q32),+12,add(13)(q32),+add(18)(q22),+20[4]	NA	NA
8	No growth	+	+
9	46,XY,t(8;14)(q24.1;q32)[cp2]/46,XY,dup(1)(q21q32),t(8;14)(q24.1;q32),der(13)t(?;13)(q11.2;p22)[cp3]/46,XY[cp15]	NA	NA
10	46,XY,t(8;14)(q24;q32)	NA	NA
11	50,X,-Y,+3,-4,+6,t(8;14)(q24.1;q32),+9,-10,+12,+19,+20,+mar[cp1]/50,X,-Y,+X,+3,+4,-5,-6,-8,+9,+10,+15,-17,+19,+20,+mar[cp1]/46,XY[cp4]	NA	NA
12	46,XY,t(8;14)(q24.1;q32)[cp6]/46,XY[cp8]	NA	NA
13	46,XX,t(8;14)(q24.1;q32)[cp1]/46,XX[cp2]	NA	NA
14	46,XY,del(6)(q21),add(7)(q32),t(8;22)(q24.1;q11),add(12)(p13)[cp19]/46,XY[cp1]	NA	NA

FISH, fluorescence in situ hybridization; IgH, immunoglobulin heavy chain; NA, not available.

study, strong TCL1 oncoprotein expression was detected in most cases of sporadic pediatric BL patient samples, consistent with previous cell line and adult BL data and suggesting that elevated TCL1 oncoprotein expression is a common event in the pathogenesis of pediatric BL. Increased TCL1 expression was observed in specimens containing and lacking EBV. The possibility that EBV– cases evolved from EBV+ B cells using a “hit-and-run” mechanism cannot be excluded formally, although a recent study of Hodgkin lymphoma failed to detect evidence for this mechanism in EBV-negative Hodgkin lymphoma cases.³¹ Our data minimally indicate that increased TCL1 expression does not depend on persistent EBV infection in BL.

Two main mechanisms have been suggested for high-level TCL1 expression in BL, including *TCL1* promoter hypomethylation and EBV infection, although possible post-transcriptional regulation has not been addressed.^{12,32} The DNA methylation status of *TCL1* in primary follicle center B cells (from which BL originates) and post-GC memory and plasma B cells is not known. However, a limited analysis of the *TCL1* core promoter in EBV– post-GC AF-10 myeloma and BC-1 primary effusion lymphoma cell lines shows that dense CpG (5'-CG-3' palindrome; p, phosphate group) methylation is not correlated with the lack of *TCL1* expression in these lines.¹³ Further studies are needed to determine the role of epigenetic regulation of *TCL1* silencing during terminal B-cell differentiation and potential epigenetic alterations that cause continued high-level expression in BL.

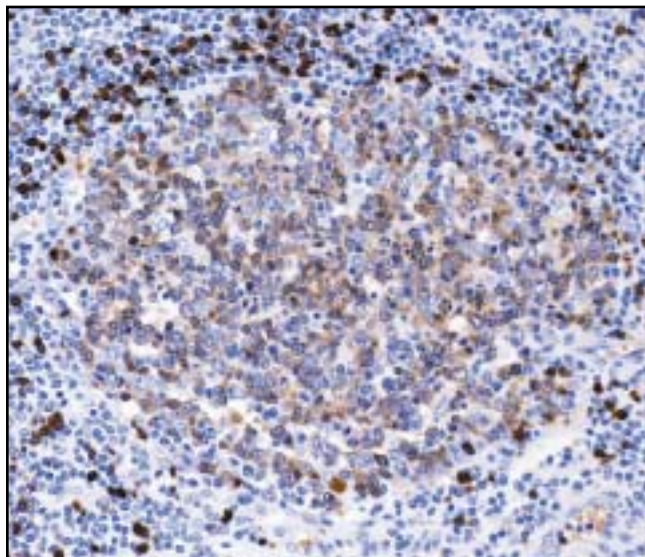


Image 3 T-cell leukemia-1 (TCL1) expression in germinal center B cells of lymphoid follicular hyperplasia. Immunohistochemical stain for TCL1 oncoprotein exhibits low intensity immunoreactivity (brown stain) in the cytoplasm of follicle center centrocytes and centroblasts (diaminobenzidine chromogen, hematoxylin counterstain, original magnification $\times 150$).

Table 3
TCL1 Expression and EBV Status in Pediatric Burkitt Lymphoma

Case No.	TCL1+ Tumor Cells (%)	TCL1 Stain		EBER Status
		Distribution	Intensity	
1	80	Nucleus	3+	–
2	60	Nucleus	3+	–
3	>90	Nucleus	3+	+
4	90	Nucleus	3+	+
5	20	Nucleus	2+	+
6	80	Nucleus	3+	–
7	0	—	—	–
8	100	Nucleus	3+	–
9	>90	Cytoplasm	3+	–
10	>90	Nucleus	3+	–
11	0	—	—	+
12	>90	Nucleus	3+	–
13	>90	Nucleus	3+	–
14	0	—	—	–
Control sample*	—	Cytoplasm/ Nucleus	1+	–

EBER, Epstein-Barr virus–encoded RNA; TCL1, T-cell leukemia-1; +, positive; –, negative; 1+, weak; 2+, moderate; 3+, strong.

* A hyperplastic tonsil from an unaffected patient.

A role for EBV in regulating *TCL1* expression is unresolved. *TCL1* expression was reported in endemic but not in sporadic BL lines, suggesting that EBV regulates *TCL1*.² EBV-immortalized fetal cord and B-lymphoblastoid cell lines also demonstrate *TCL1* expression.^{2,11,33} Most recently, latency I EBV+ Akata BL cells that spontaneously lose EBV produced

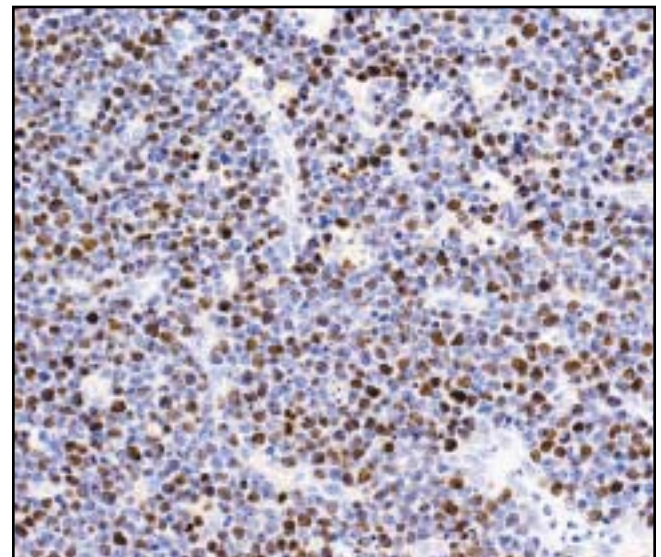


Image 4 Epstein-Barr virus status in pediatric Burkitt lymphoma. In situ hybridization for Epstein-Barr virus–encoded RNA exhibits reactivity (brown stain) in the nucleus of Burkitt lymphoma cells (diaminobenzidine chromogen, hematoxylin counterstain, original magnification $\times 150$).

subclones with reduced *TCL1* expression.³² EBV reinfection into the EBV– BL subclones restored *TCL1* expression to about 60% of its original level. In contrast with these observations, EBV– DLBCL cases often expressed abundant *TCL1*.⁸ Also, in a separate study, sporadic and endemic BL lines expressed *TCL1*, whereas matched EBV+ and EBV– lines showed similar levels of *TCL1* expression.¹¹ Results from the present study also showed that high-level *TCL1* expression does not depend on concurrent EBV infection. Combined, the data indicate many possibilities, but to establish or negate a direct role for EBV requires linking viral components directly with *TCL1* gene and/or posttranscriptional regulation.

TCL1 oncoprotein levels decrease in follicular B cells, similar to the decreased expression of *BCL-2* in GCs.^{8,10,11} Because B cells undergo selection pressure for appropriate antibody affinities at this stage of development, this finding supports the idea that *TCL1* is cell-protective and is down-regulated to facilitate B-cell selection.⁸ Increased *TCL1* expression in GC-derived pediatric BL suggests an aberrant cell-protective mechanism, like *BCL-2* in follicular lymphoma. In mouse B cells, *bcl-2* is poorly oncogenic, with slow development (>12 months) and low penetrance (10%-15%) of the malignant phenotype.³⁴ Coexpression of *c-myc* with *bcl-2* dramatically increases the rate and penetrance of B-lymphoid tumors in transgenic mice.³⁴ There is an interesting parallel between this situation, in which prosurvival *bcl-2* augments *c-myc* transformation, and the situation reported herein for *TCL1*, in which prosurvival *TCL1* is overexpressed in BL cases that contain *c-MYC/IgH* translocations causing dysregulated expression of the *c-MYC* proto-oncogene.³⁵ This parallel suggests a potential synergistic, cell-protective role for increased *TCL1* oncoprotein expression in the development of *c-MYC*–expressing pediatric BL cases.

Transgenic mice with increased *TCL1* in B-cell lymphocytes have a very high frequency of aggressive B-cell lymphomas that resemble BL and DLBCL.⁷ It will be interesting to determine the *c-myc* expression status in Burkitt-like tumor cells that arise in these transgenic mice. These mice might provide a useful model for EBV– BL to study the pathogenesis and potential novel therapeutic strategies, perhaps including molecules directed toward the interaction of *TCL1* with Akt.^{6,36-38} Overall, the *TCL1* oncoprotein is expressed strongly in most pediatric BL cases. However, persistent EBV is not essential for increased *TCL1* expression, which might be required along with dysregulated *c-MYC* for the development of most BL cases.

From the ¹Department of Pathology and Laboratory Medicine and ²Molecular Biology Institute, Jonsson Comprehensive Cancer Center, Center for Cell Mimetic Studies and California NanoSystems Institute, David Geffen School of Medicine at UCLA, Los Angeles, CA; ³Department of Pathology, Children's Hospital of Orange County/St Joseph Hospital, Orange, CA; ⁴Children's

Cancer Group (now part of Children's Oncology Group), Arcadia, CA; ⁵Department of Pathology, University of Utah Health Sciences Center, Salt Lake City; ⁶Center for Human Genetics, University of Nebraska Medical Center, Omaha; ⁷Department of Pediatrics, Children's Hospital of New York Presbyterian, Columbia University, New York, NY.

Supported in part by grants from the Lymphoma Research Foundation (Dr Said); R01CA90571 and R01CA107300 (Dr Teitell) from the National Cancer Institute, National Institutes of Health, Bethesda, MD; the Margaret E. Early Medical Research Trust (Dr Teitell); grant NCC2-1364 (Dr Teitell) from the Center for Cell Mimetic Studies; Pediatric Cancer Research Foundation and Andrew J. Gargiso Foundation (Dr Cairo); and the Division of Cancer Treatment, National Cancer Institute, National Institutes of Health, Department of Health and Human Services. (A complete listing of grant support for research conducted by Children's Cancer Group and Pediatric Oncology Group before initiation of the Children's Oncology Group grant in 2003 is available online at:

<http://www.childrensoncologygroup.org/admin/grantinfo.htm>.)

Dr Teitell is a scholar of the Leukemia and Lymphoma Society, White Plains, NY.

Address reprint requests to Dr Lones: Children's Oncology Group, PO Box 60012, Arcadia, CA 91066-6012.

Acknowledgments: We thank I. Peter Shintaku, PhD, and Diane L. Pickering for outstanding technical assistance.

References

- Virgilio L, Isobe M, Narducci MG, et al. Chromosome walking on the *TCL1* locus involved in T-cell neoplasia. *Proc Natl Acad Sci U S A*. 1993;90:9275-9279.
- Virgilio L, Narducci MG, Isobe M, et al. Identification of the *TCL1* gene involved in T-cell malignancies. *Proc Natl Acad Sci U S A*. 1994;91:12530-12534.
- Laine J, Kunstle G, Obata T, et al. The protooncogene *TCL1* is an Akt kinase coactivator. *Mol Cell*. 2000;6:395-407.
- Pekarsky Y, Koval A, Hallas C, et al. *Tcl1* enhances Akt kinase activity and mediates its nuclear translocation. *Proc Natl Acad Sci U S A*. 2000;97:3028-3033.
- Kunstle G, Laine J, Pierron G, et al. Identification of Akt association and oligomerization domains of the Akt kinase coactivator *TCL1*. *Mol Cell Biol*. 2002;22:1513-1525.
- French SW, Shen RR, Koh PJ, et al. A modeled hydrophobic domain on the *TCL1* oncoprotein mediates association with AKT at the cytoplasmic membrane. *Biochemistry*. 2002;41:6376-6382.
- Hoyer KK, French SW, Turner DE, et al. Dysregulated *TCL1* promotes multiple classes of mature B cell lymphoma. *Proc Natl Acad Sci U S A*. 2002;99:14392-14397.
- Teitell M, Damore MA, Sullur GG, et al. *TCL1* oncogene expression in AIDS-related lymphomas and lymphoid tissues. *Proc Natl Acad Sci U S A*. 1999;96:9809-9814.
- Virgilio L, Lazzeri C, Bichi R, et al. Deregulated expression of *TCL1* causes T-cell leukemia in mice. *Proc Natl Acad Sci U S A*. 1998;95:3885-3889.
- Narducci MG, Pescarmona E, Lazzeri C, et al. Regulation of *TCL1* expression in B- and T-cell lymphomas and reactive lymphoid tissues. *Cancer Res*. 2000;60:2095-2100.

11. Said JW, Hoyer KK, French SW, et al. *TCL1* oncogene expression in B cell subsets from lymphoid hyperplasia and distinct classes of B cell lymphoma. *Lab Invest.* 2001;81:555-564.
12. Yuille MR, Condie A, Stone EM, et al. *TCL1* is activated by chromosomal rearrangement or by hypomethylation. *Genes Chromosomes Cancer.* 2001;30:336-341.
13. French SW, Malone CS, Shen RR, et al. Sp1 transactivation of the *TCL1* oncogene. *J Biol Chem.* 2003;278:948-955.
14. Klein G. Studies on the Epstein-Barr virus genome and the EBV-determined nuclear antigen in human malignant disease. *Cold Spring Harb Symp Quant Biol.* 1975;39 pt 2:783-790.
15. Cairo MS, Gerrard M, Patte C. A new protocol for treatment of mature B-cell lymphoma/leukemia (BCLL): FAB LMB 96: a SFOP LMB 96/CCG-5961/UKCCSG 9600 international cooperative study [abstract]. *Med Pediatr Oncol.* 1997;29:357A.
16. Gerrard M, Cairo M, Weston C, et al. Results of the FAB international study in children and adolescents with localized, resected B cell lymphoma (large cell, Burkitt and Burkitt-like) [abstract]. *Proc Am Soc Clin Oncol.* 2003;22:795A.
17. Patte C, Gerrard M, Auperin A, et al. Results of the randomized international trial FAB LMB 96 for the "intermediate risk" childhood and adolescent B-cell lymphoma: reduced therapy is efficacious [abstract]. *Proc Am Soc Clin Oncol.* 2003;22:796A.
18. Cairo M, Gerrard M, Sposto R, et al. Results of a randomized FAB LMB 96 international study in children and adolescents with advanced (bone marrow [B-ALL] and/or CNS) B-NHL (large cell, Burkitt's and Burkitt-like): pts with L3 leukemia/CNS- have an excellent prognosis [abstract]. *Proc Am Soc Clin Oncol.* 2003;22:796A.
19. Murphy SB. Classification, staging and end results of treatment of childhood non-Hodgkin's lymphomas: dissimilarities from lymphomas in adults. *Semin Oncol.* 1980;7:332-339.
20. Harris NL, Jaffe ES, Stein H, et al. A revised European-American classification of lymphoid neoplasms: a proposal from the International Lymphoma Study Group. *Blood.* 1994;84:1361-1392.
21. Jaffe ES, Harris NL, Stein H, et al, eds. *Pathology and Genetics of Tumours of Haematopoietic and Lymphoid Tissues.* Lyon, France: IARC Press; 2001. *World Health Organization Classification of Tumours.*
22. Lones MA, Cairo MS, Perkins SL. T-cell-rich large B-cell lymphoma in children and adolescents: a clinicopathologic report of six cases from the Children's Cancer Group Study CCG-5961. *Cancer.* 2000;88:2378-2386.
23. Lones MA, Lopez-Terrada D, Shintaku IP, et al. Posttransplant lymphoproliferative disorder in pediatric bone marrow transplant recipients: disseminated disease of donor origin demonstrated by fluorescence in situ hybridization. *Arch Pathol Lab Med.* 1998;122:708-714.
24. Mitelman F, ed. *ISCN. 1995: An International System for Human Cytogenetic Nomenclature 1995.* Basel, Switzerland: S Karger; 1995.
25. Sandlund JT, Downing JR, Crist WM. Non-Hodgkin's lymphoma in childhood. *N Engl J Med.* 1996;334:1238-1248.
26. Murphy SB, Fairclough DL, Hutchison RE, et al. Non-Hodgkin's lymphomas of childhood: an analysis of the histology, staging, and response to treatment of 338 cases at a single institution. *J Clin Oncol.* 1989;7:186-193.
27. Perkins SL, Lones MA, Davenport V, et al. B-cell non-Hodgkin's lymphoma in children and adolescents: surface antigen expression and clinical implications for future targeted bioimmune therapy: a Children's Cancer Group Report. *Clin Adv Hematol Oncol.* 2003;1:314-317.
28. Lones MA, Sanger WG, Le Beau MM, et al. Chromosome abnormalities may correlate with prognosis in Burkitt/Burkitt-like lymphomas of children and adolescents: a report from Children's Cancer Group Study CCG-E08. *J Pediatr Hematol Oncol.* 2004;26:169-178.
29. Sanger W, Lones M, Perkins S, et al. Chromosome abnormalities in B-cell non-Hodgkin lymphoma of children and adolescents: a report from Children's Cancer Group Study CCG-5961 [abstract]. *Ann Oncol.* 2002;13(suppl 2):45A.
30. Takizawa J, Suzuki R, Kuroda H, et al. Expression of the *TCL1* gene at 14q32 in B-cell malignancies but not in adult T-cell leukemia. *Jpn J Cancer Res.* 1998;89:712-718.
31. Gallagher A, Perry J, Freeland J, et al. Hodgkin lymphoma and Epstein-Barr virus (EBV): no evidence to support hit-and-run mechanism in cases classified as non-EBV-associated. *Int J Cancer.* 2003;104:624-630.
32. Kiss C, Nishikawa J, Takada K, et al. T cell leukemia I oncogene expression depends on the presence of Epstein-Barr virus in the virus-carrying Burkitt lymphoma lines. *Proc Natl Acad Sci U S A.* 2003;100:4813-4818.
33. Pekarsky Y, Hallas C, Isobe M, et al. Abnormalities at 14q32.1 in T cell malignancies involve two oncogenes. *Proc Natl Acad Sci U S A.* 1999;96:2949-2951.
34. Cory S, Vaux DL, Strasser A, et al. Insights from *bcl-2* and *myc*: malignancy involves abrogation of apoptosis as well as sustained proliferation. *Cancer Res.* 1999;59:1685s-1692s.
35. Klein G. Dysregulation of lymphocyte proliferation by chromosomal translocations and sequential genetic changes. *Bioessays.* 2000;22:414-422.
36. Lock RB. *TCL1*: a new drug target in lymphoid and germ-cell malignancies? *Int J Biochem Cell Biol.* 2003;35:1614-1618.
37. Auguin D, Barthe P, Royer C, et al. Structural basis for the co-activation of protein kinase B by T-cell leukemia-1 (*TCL1*) family proto-oncoproteins. *J Biol Chem.* 2004;279:35890-35902.
38. Hiromura M, Okada F, Obata T, et al. Inhibition of Akt kinase activity by a peptide spanning the betaA strand of the proto-oncogene *TCL1*. *J Biol Chem.* 2004;279:53407-53418.